

# Sonography of Elbow & Wrist

Musculoskeletal Ultrasound Hands-on Workshop

**Chueh-Hung Wu, MD, PhD**

National Taiwan University Hospital  
Musculoskeletal Ultrasound Center

Anatomy, surface bony landmark

Adequate positioning

Patient

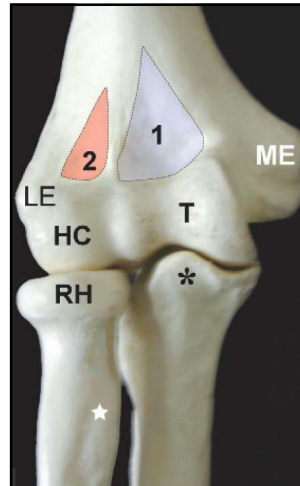
Transducer

Proper setting of the machine

Frequency, focus, intensity, gain, etc

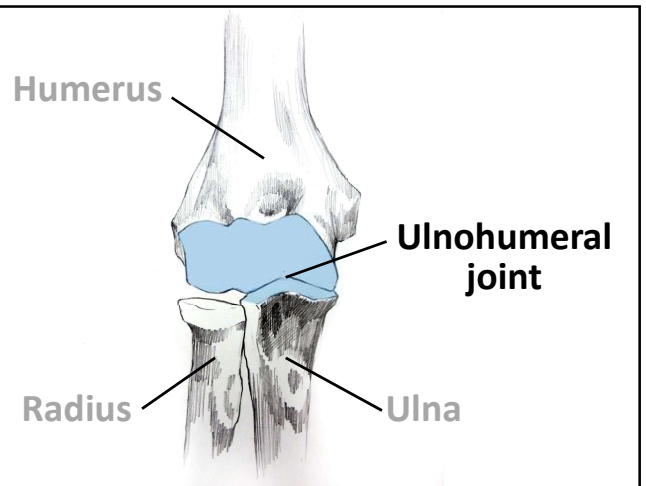
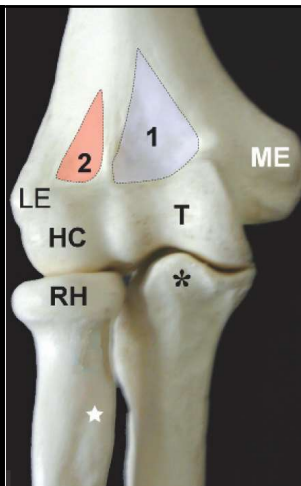
To get a good image

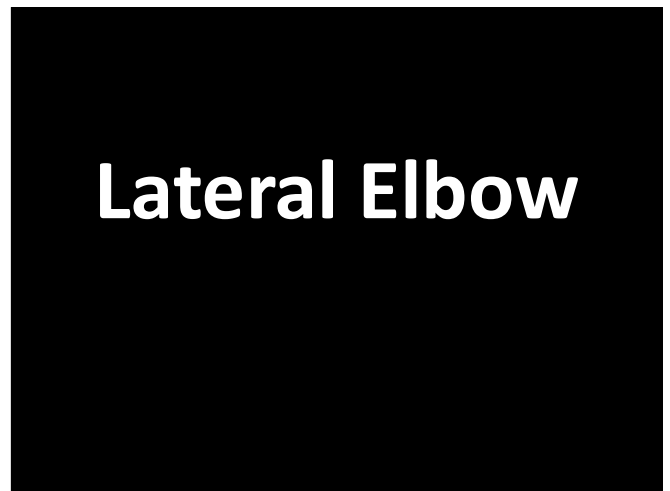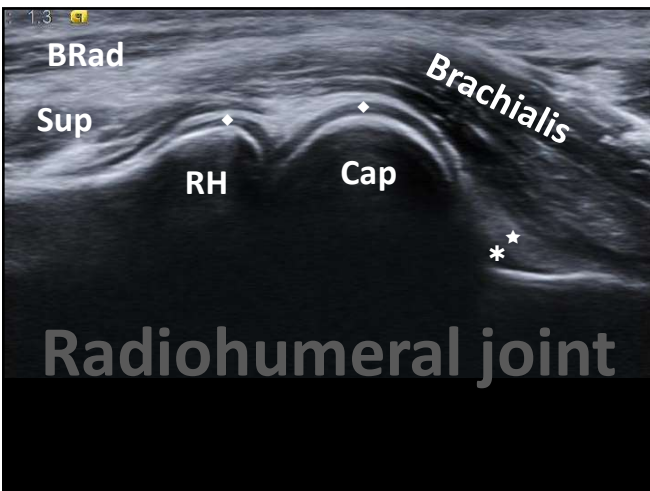
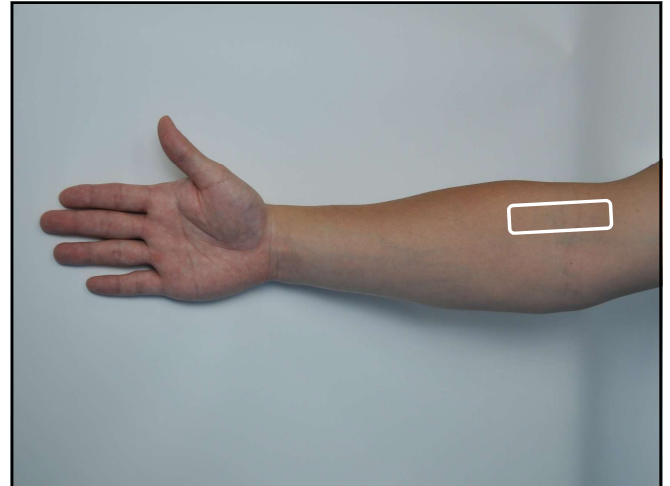
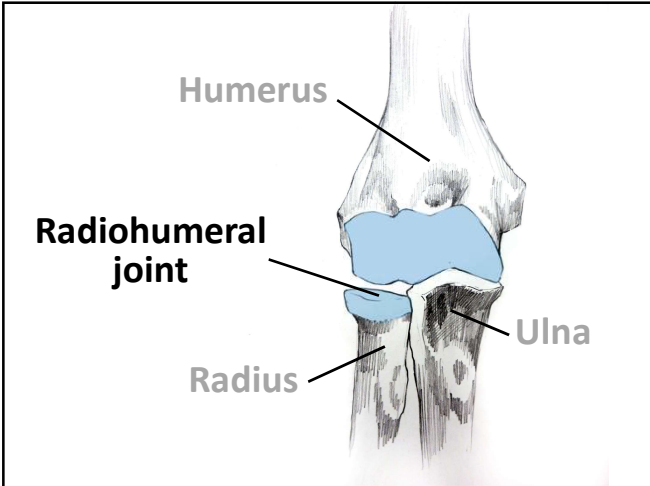
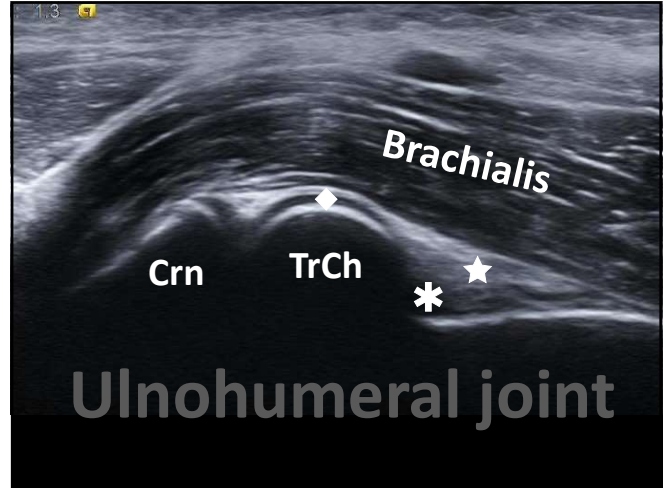
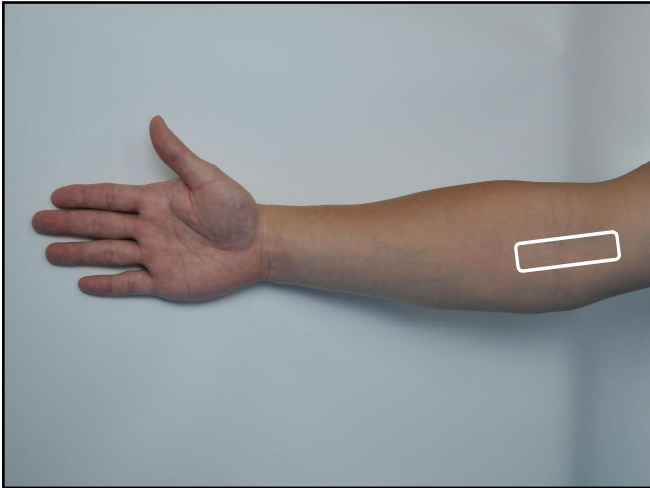
## Anterior Elbow

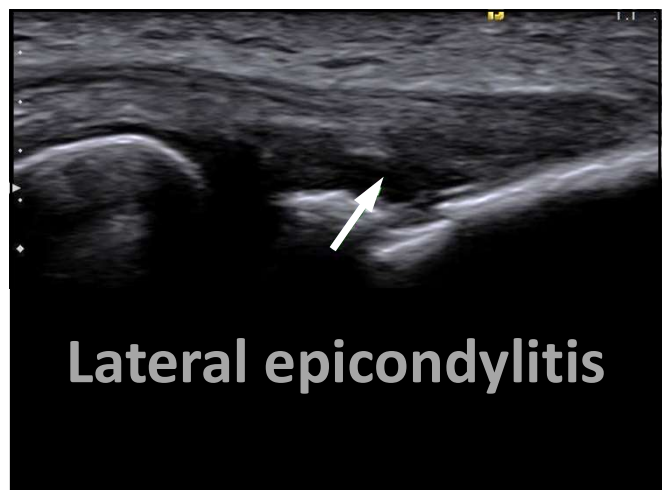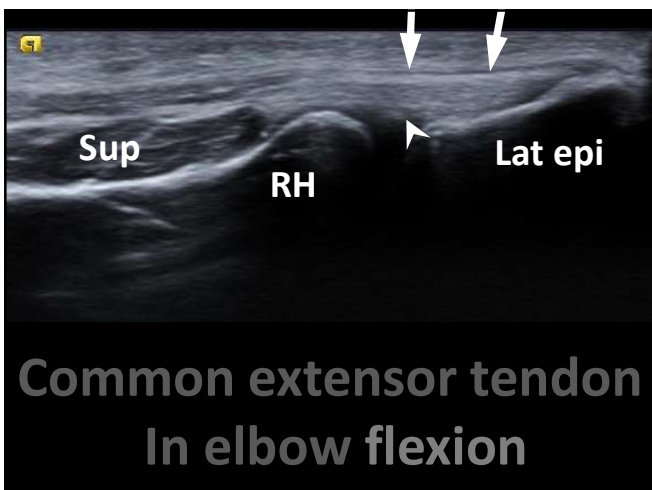
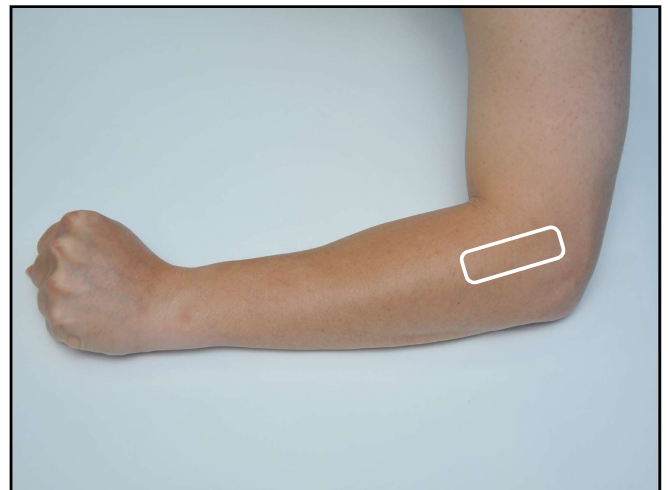
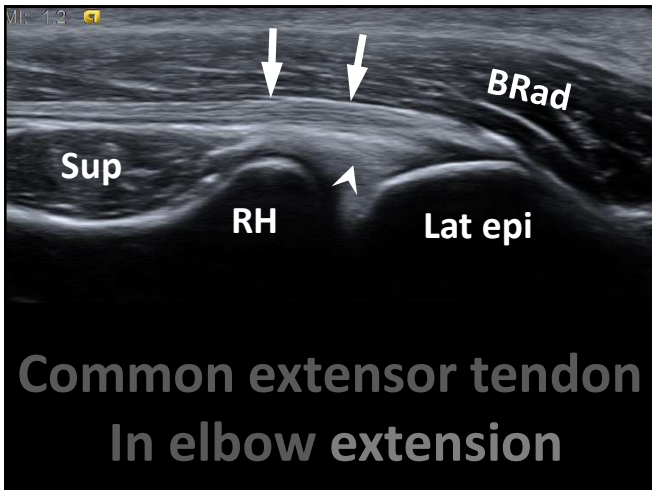
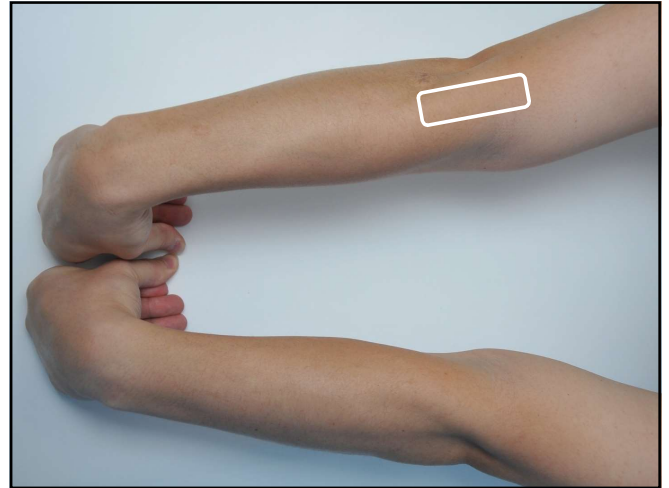
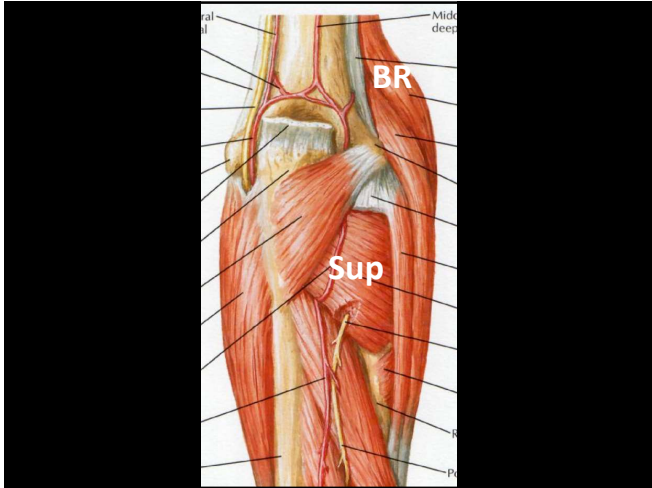


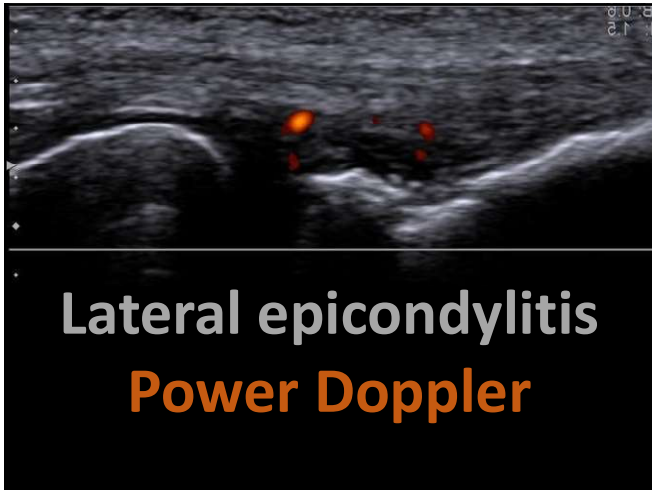
ME: medial epicondyle  
1: coronoid fossa  
T: Trochlea  
\*: coronoid process

LE: lateral epicondyle  
2: radial fossa  
HC: humerus capitellum  
RH: radial head

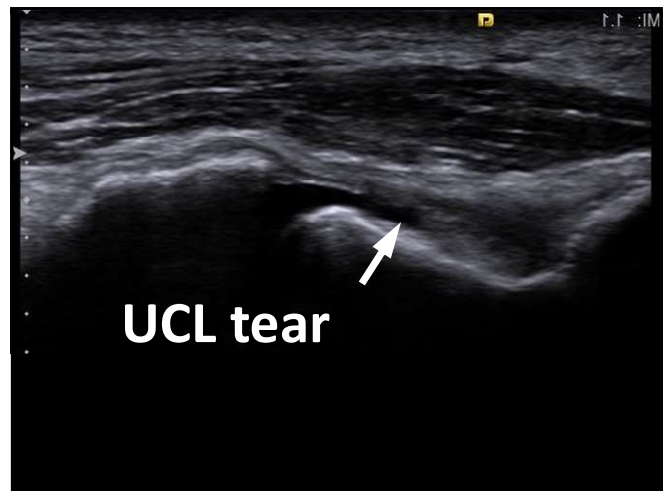
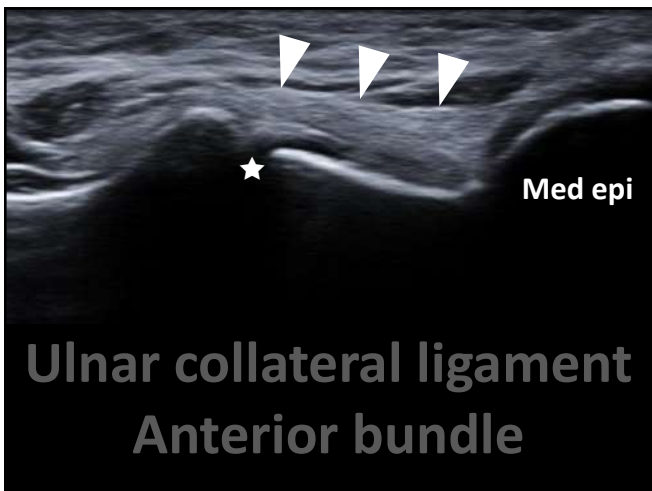
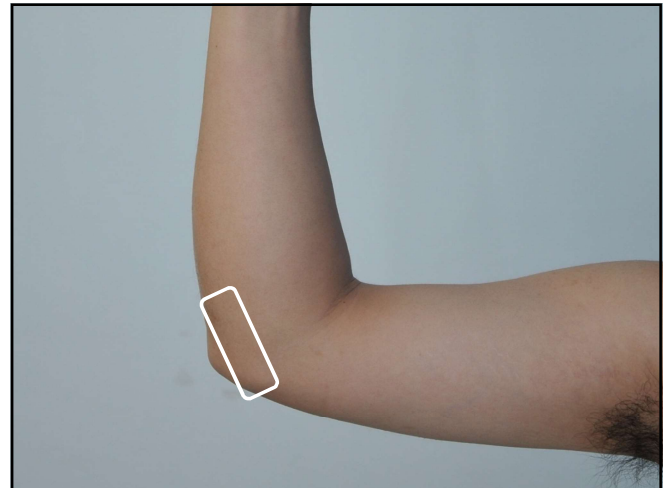
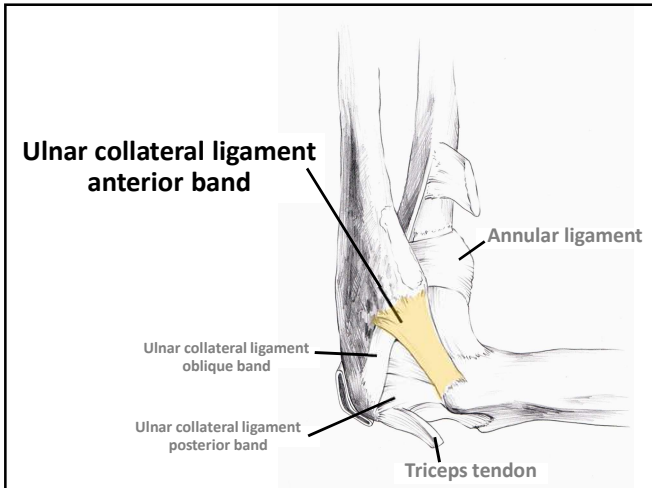




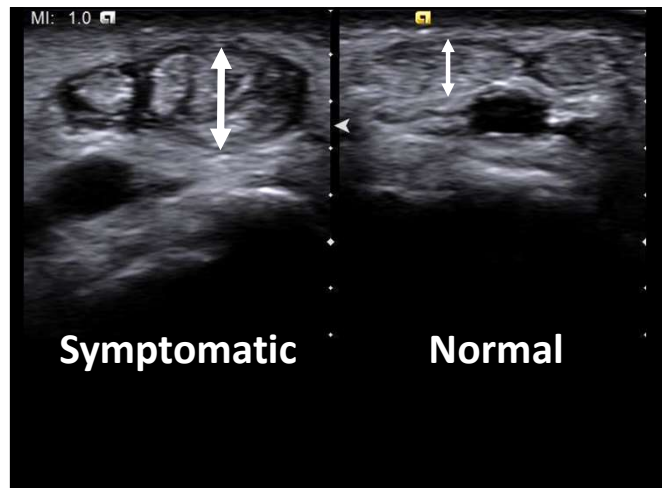
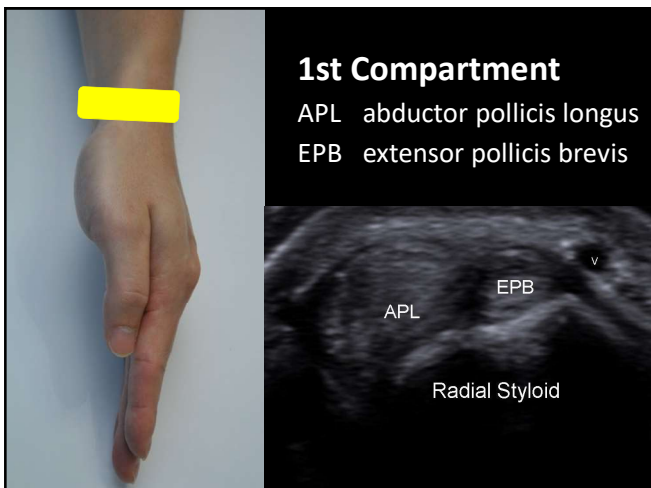
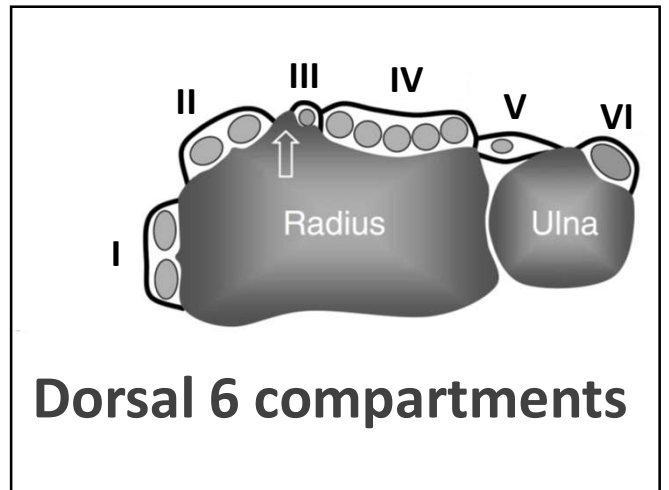
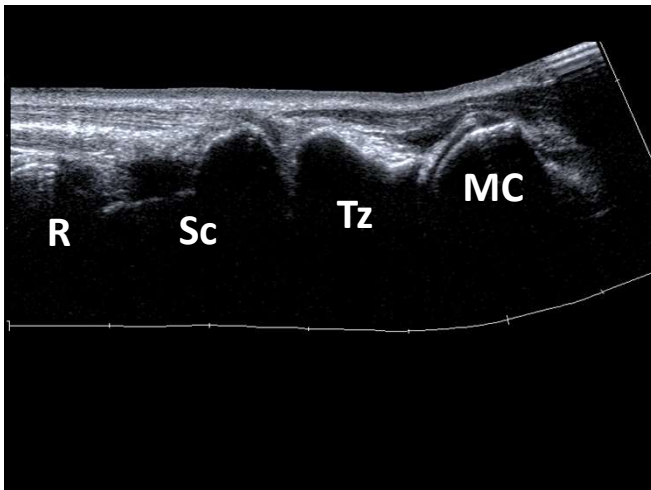
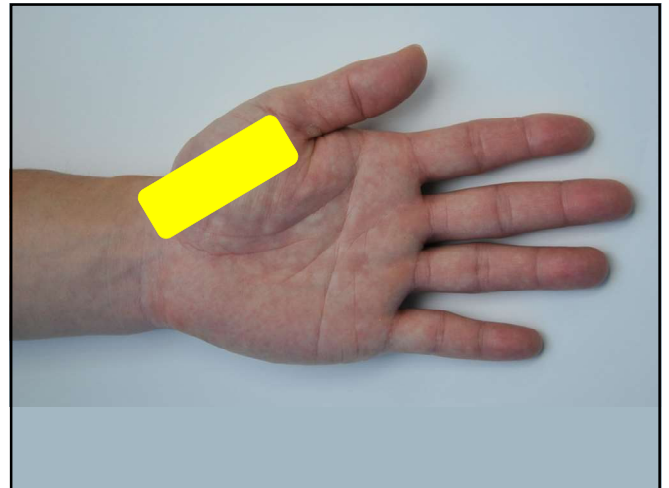
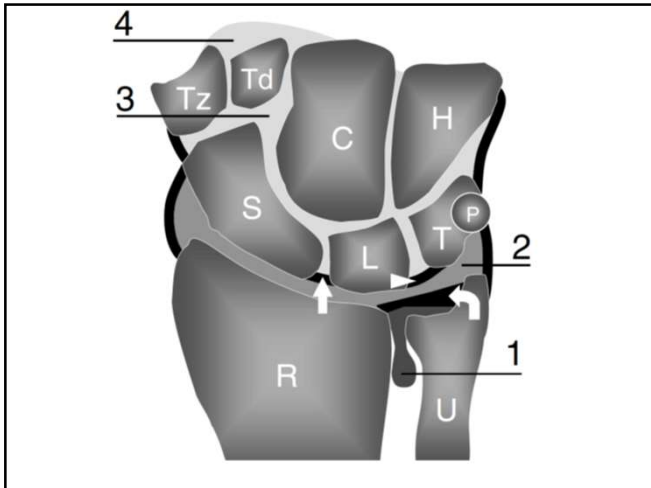


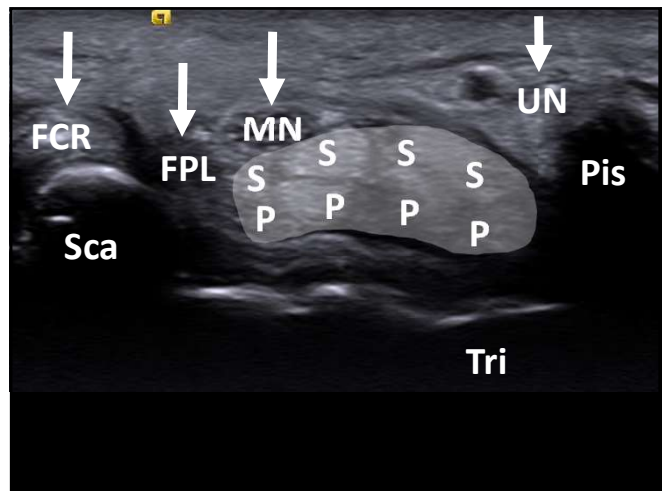
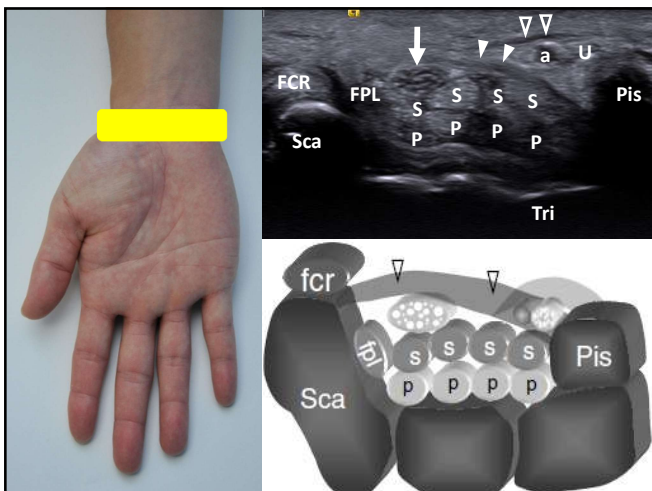
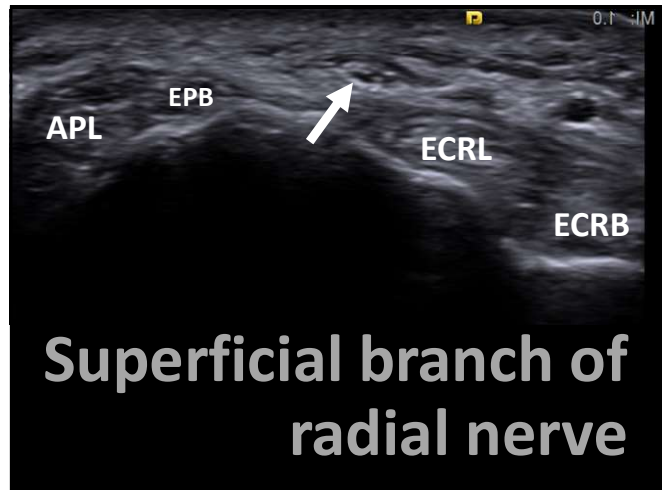
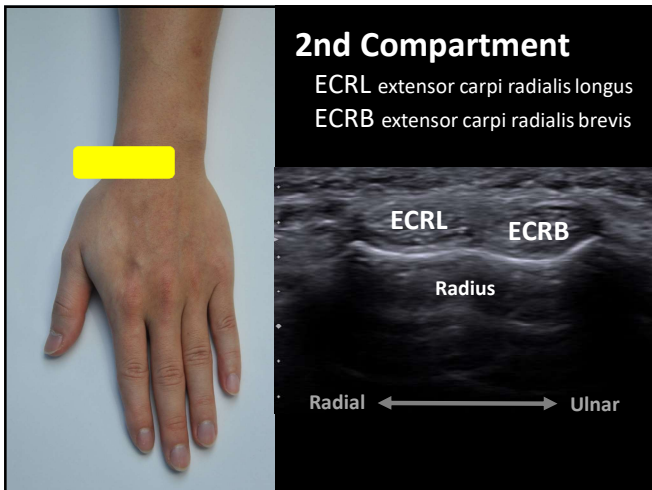
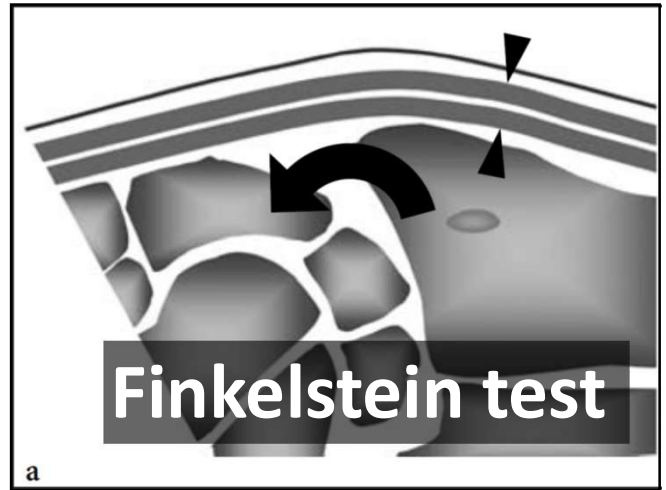
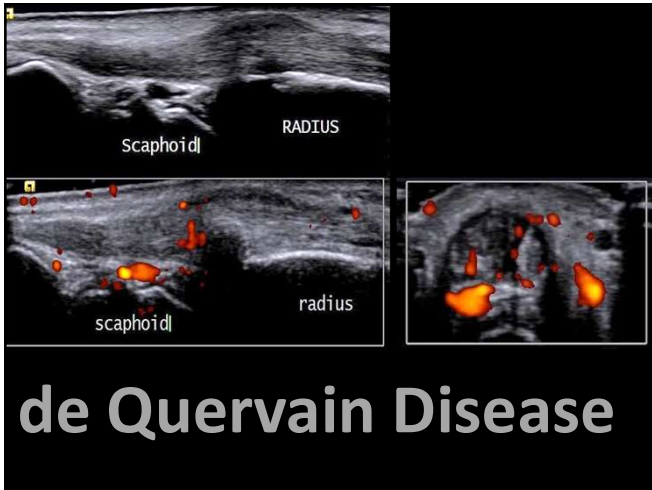


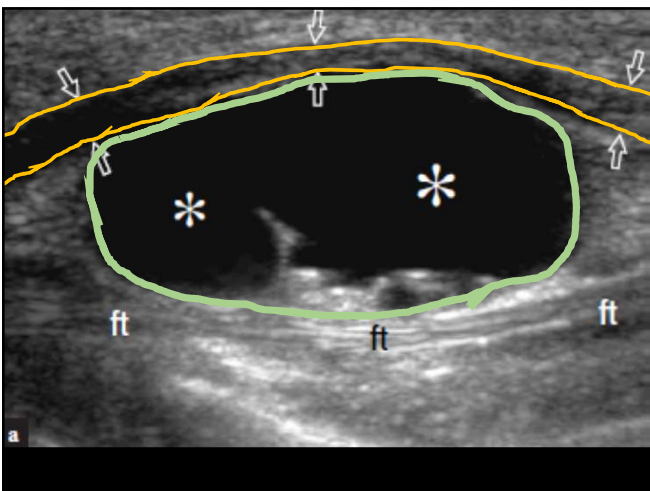
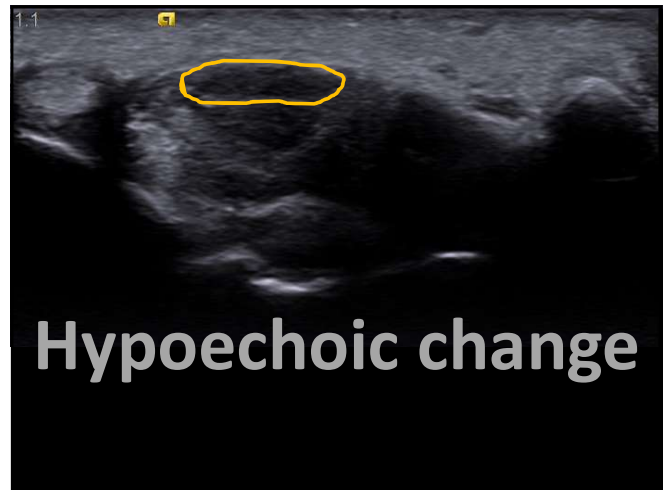
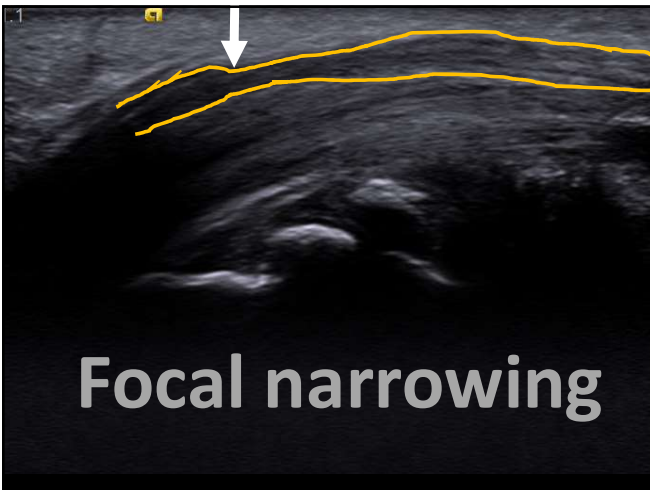
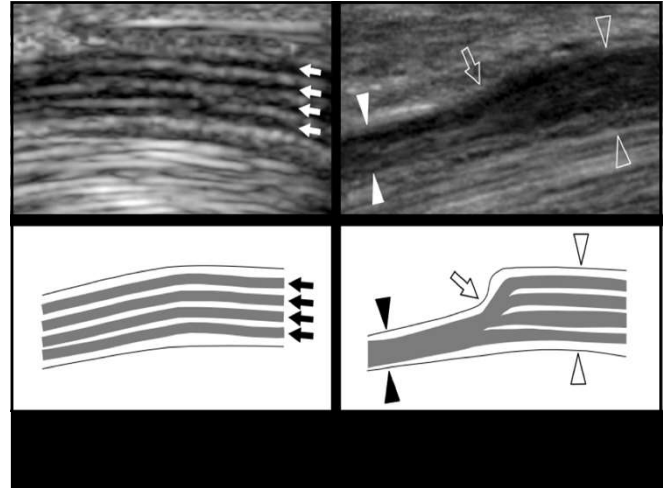
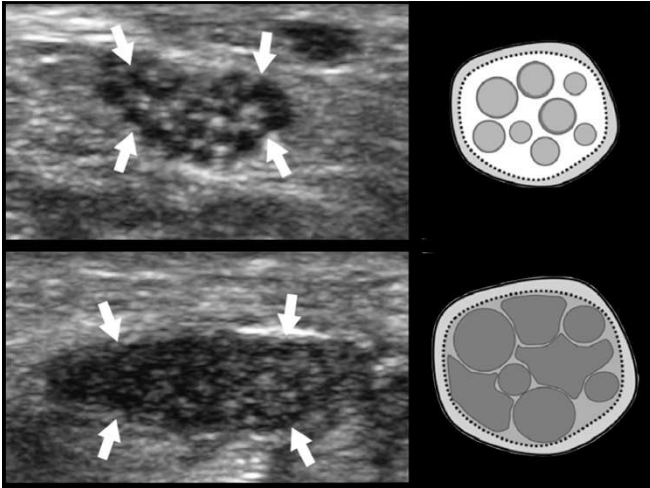
# Medial Elbow











**Elbow joint – effusion, arthritis**  
**Lateral epicondyle– tennis elbow**  
**Medial UCL – pitchers**  
**Radiocarpal / CMC joint – arthritis**  
**APL/EPB – De Quervain disease**  
**Median n – Carpal tunnel syndrome**